

# Early Implantation with oval, not rotating Implant ROSI™

Generally, the gap is nowadays regarded as an indication for implantation, provided the medical history permits it.

In implantology, it is considered priority to achieve very high primary stability, i.e. the inserted implant does not move in the bone. This is to be achieved when the implant has the widest possible bone contact and surrounding of the implant is as firm as possible.

It is very important that there are no micro-movements during the healing phase which would prevent osseointegration and would lead to periimplantitis.

During the healing phase we see a remodeling of the damaged surrounding of the implant – damaged by drilling, heat, haematoma and contusion.

In the case of the use of a screw implant the bone tissue is contused with torque up to 80 Ncm (according to the manufacturer's recommendation).

The stability of the just inserted Implant mainly depends of the condition of the cortex and its close contact to the implant.

In the immediate and early implantation close contact to alveolar bone improves the primary stability significantly. Furthermore, bony interdental papilla is als well advantageous.

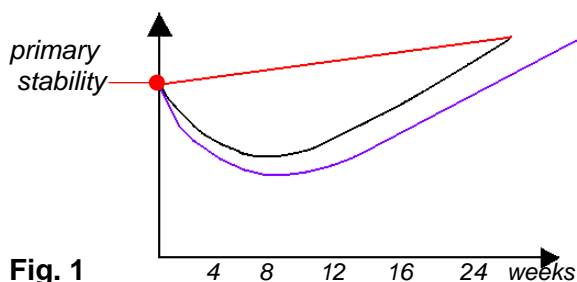


Fig. 1

*Development of stability in oval, not rotating implant without thread (ROSI™ by Dr. Böhm).*

*Development of stability with a continuous screw thread.*

*Development of stability screw threads only in the spongy bone.*

## Case Study:

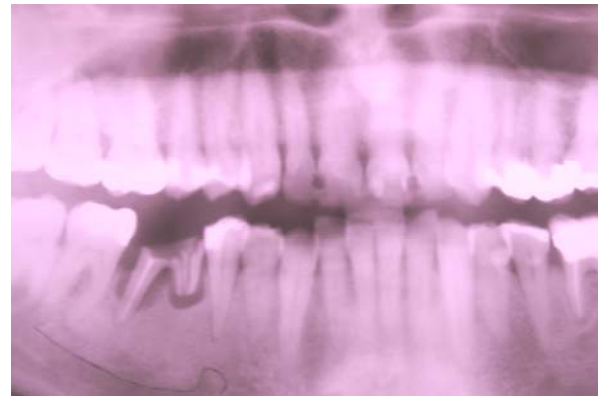


Fig. 2

61-year-old male patient, smoker.  
broken tooth 46 (Fig. 2).

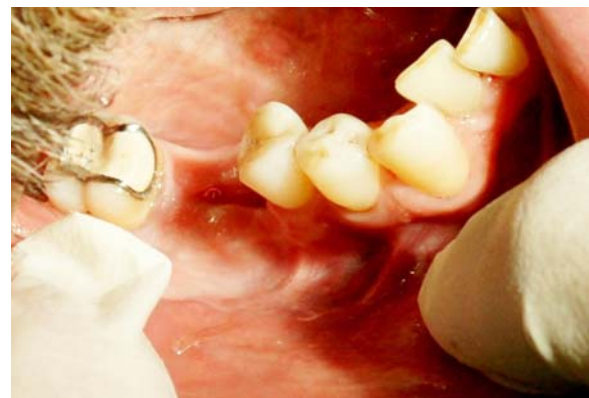

Fig. 3

State two weeks after extraction of tooth 46 (Fig. 3).

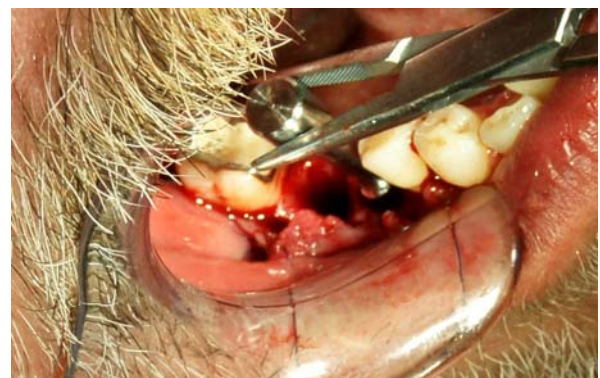
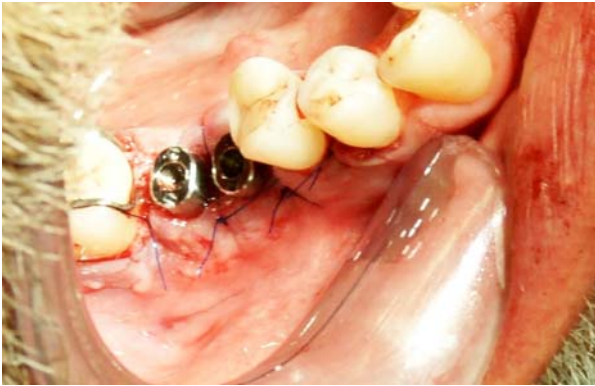
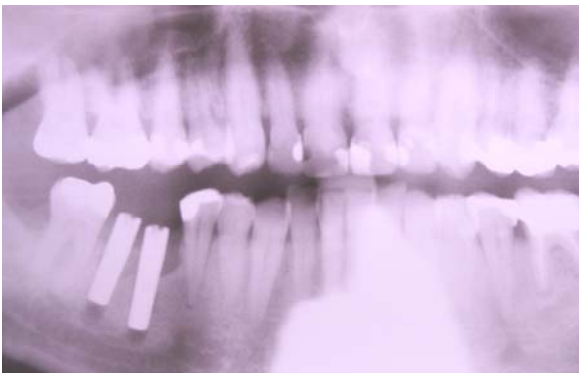Fig. 4

Flap, stepwise cylindrical bore diameter in both alveoli up to 4 mm. Applying the probe for determining the tilt of 1.5 mm with 3,5 mm drill non cutting (blunt) tip (Fig. 4) for receiving the 13 mm long oval implants.



**Fig. 5**

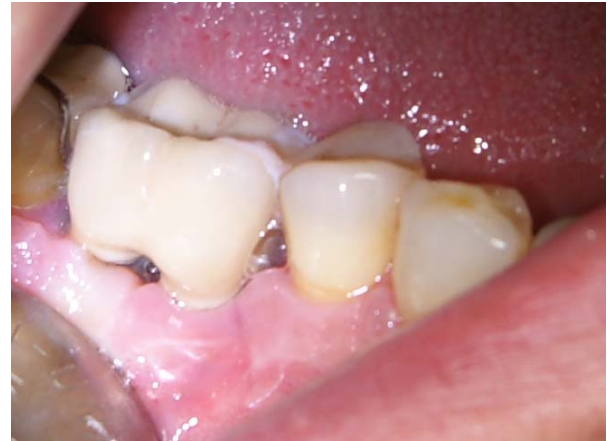The oval, not rotating implants ROSI™ were inserted together with healing post, pressed with fingers into the cavity and fixed with light hammer blow. Subsequently, the gingiva was adapted with a thin atraumatic suture (Fig. 5).



**Fig. 6**

Fig. 6 shows x-ray, state after insertion of the two 13 mm long, not rotationally symmetric ROSI™ - implants with attached healing post, height 5mm.

Measurement with Resonance Frequency Analysis (RFA) with Periotest™ (Medizintechnik Gulden) was immediately after the insertion of implants for both implants +1. Periotest™ values between -8 and +9 correspond to a measurement with fingers degree 0. The following measurements after 1, 2. and 3 weeks were also with fingers degree 0. There always was clear sound, which suggests a high stability. The Periotest™ - values were +0.9 and +1.7 after 3 weeks.



**Fig. 7**

Four weeks after implantation a Zr-crown was cementated (Fig. 7). Without crown the Periotest™ values were distal root 0.0 and mesial -2.6 and, well above the primary stability at insertion.

The RFA measurement with Periotest™ after inserting the Crown gave -4.5. This is a value which is well above the average values of lower molars.

### Summary:

According to *S. Raghavendra et al. 2005* most implant failures occur in the critical early healing between the second and fourth week. Here is seen a gap of stability according to *Raghavendra* by a decrease in the primary stability and the slow increase of secondary stability in the end of the healing process.

As for ROSI™ implants apparently there is no decrease to realize at this time, much-more, the stability increases slowly compared to the initial stability since insertion.

Mastication was possible immediately after cementation of the crown.

The reduced healing time brings to patient and entire treatment significant benefits. Therefor implantation generally can carried out with single tooth implants - an important influence on dental care planning.

**Photos:** Jürgen Grösel

Graphic to the study by Dr. G. Stein

